

IMAGING PERFORMED BY

PAMobileVet.com 443-794-4700

PATIENT PRESENTING CLINICAL SIGNS

History: Lump on right side of neck, painful

SPECIES ULTRASONOGRAPHIC EXAMINATION OF THE NECK

Canine

BREED

Beagle Mix

SEX

Neutered Male

AGE

7 years

ULTRASONOGRAPHIC FINDINGS

- Large non-homogeneous ventral neck mass in area of the right thyroid gland

WEIGHT

34.4 Pounds

INTERPRETATION OF THE FINDINGS & FURTHER RECOMMENDATIONS

Based on sonographic appearance and location, a neoplastic process involving the right thyroid is likely. Thyroid carcinoma is considered the primary differential diagnosis in this case. Ultrasound guided fine needle aspirate of the ventral neck mass was obtained during the ultrasound without complication for screening cytology. Pending cytology, cross sectional imaging of the neck is likely ideal for assessment of surgical resectability, and non-obvious evidence of regional metastasis. 3-view chest radiographs are recommended if not done.

INTERPRETED BY

R. McKenzie Daniel,
DVM, DABVP
(Canine and Feline)

IMAGING PERFORMED BY

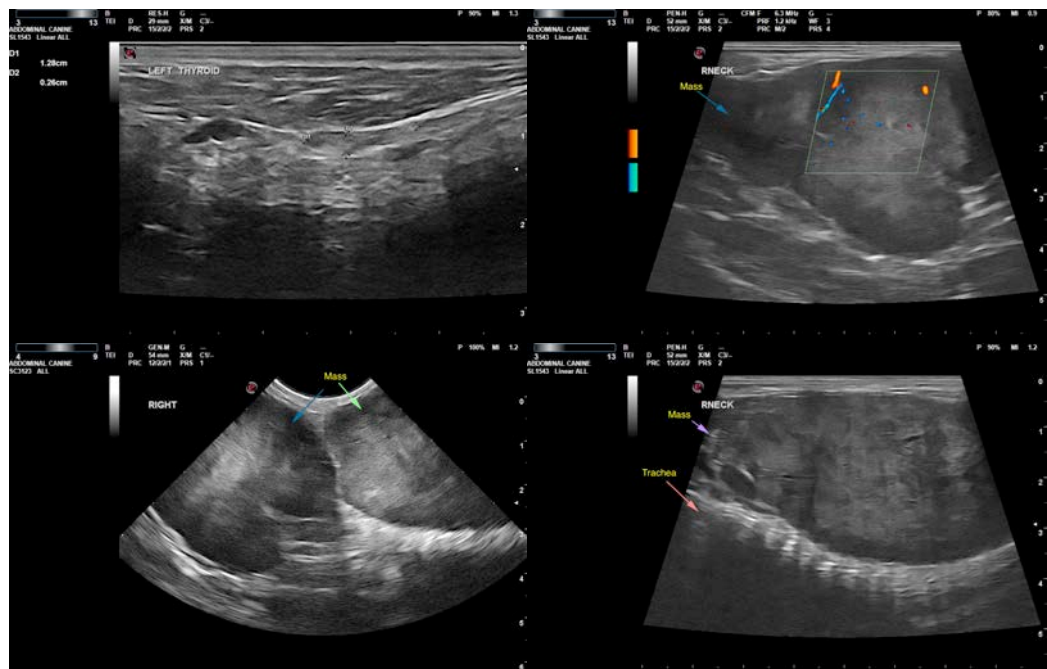
Rebekah Jakum, CVT
ARDMS/RVT

HOSPITAL NAME

REFERRING VET

INVOICE

DATE



IMAGING PERFORMED BY

PAMobileVet.com 443-794-4700

PATIENT

SPECIES

Canine

BREED

Beagle Mix

SEX

Neutered Male

AGE

7 years

WEIGHT

34.4 Pounds

INTERPRETED BY

R. McKenzie Daniel,
DVM, DABVP
(Canine and Feline)

**IMAGING
PERFORMED BY**

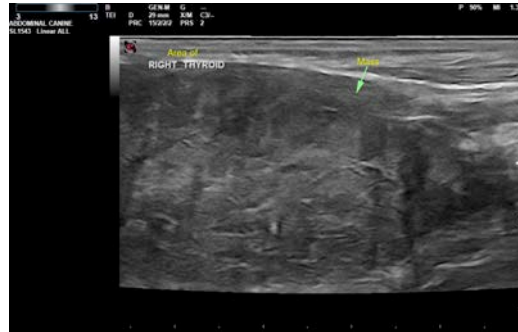
Rebekah Jakum, CVT
ARDMS/RVT

HOSPITAL NAME

REFERRING VET

INVOICE

DATE



The information and recommendations provided are based on the images presented by the referring veterinarian. No evaluation can be communicated regarding pathology that was not visible in the image/video clips provided.

Thank you for this referral. If the clinical or image interpretation does not parallel your findings or if I can be of any further assistance please contact me.